

EMORY

SPORTS MEDICINE
CENTER

COMMON INJURIES IN YOUTH SOCCER

Amadeus Mason, MD
Courtney Gleason, MD
Emory Sports Medicine
Emory Soccer Medicine Conference
January 12, 2019

EMORY
SPORTS MEDICINE
CENTER



Common Pediatric Injuries

CDC data, more than 2.6 million kids under the age of 19 are treated in the emergency department every year for sports and recreation-related injuries

The growing skeleton in the pediatric athlete puts them at risk for injuries and conditions that are different from adults



Common Pediatric Soccer Injuries



Overuse Injuries

Acute Injuries

Overuse Injuries



Estimated to account for 45.9% to 54% of all youth sport injuries

Result from an imbalance between training and load to the tissues and recovery time

The apophyses and physes (growth plates) are the “weak link” of the musculoskeletal system in kids



Case 1

13 year-old male soccer player
with anterior knee pain

Symptoms present for 6 weeks,
worsening

Reports swelling in the anterior
knee and pain worse with activity

Plays on 2 soccer teams in the fall
and spring and 2 basketball teams
in the winter

No history of specific injury

Physical exam:

- Non-antalgic gait
- Swelling over the distal aspect of the anterior knee, no knee effusion
- Range of motion is full
- Tenderness to palpation over the tibial tubercle
- Quadriceps tightness on flexibility testing (Ely testing)



Osgood-Schlatter Disease

Common causes of anterior knee pain
in an active adolescent

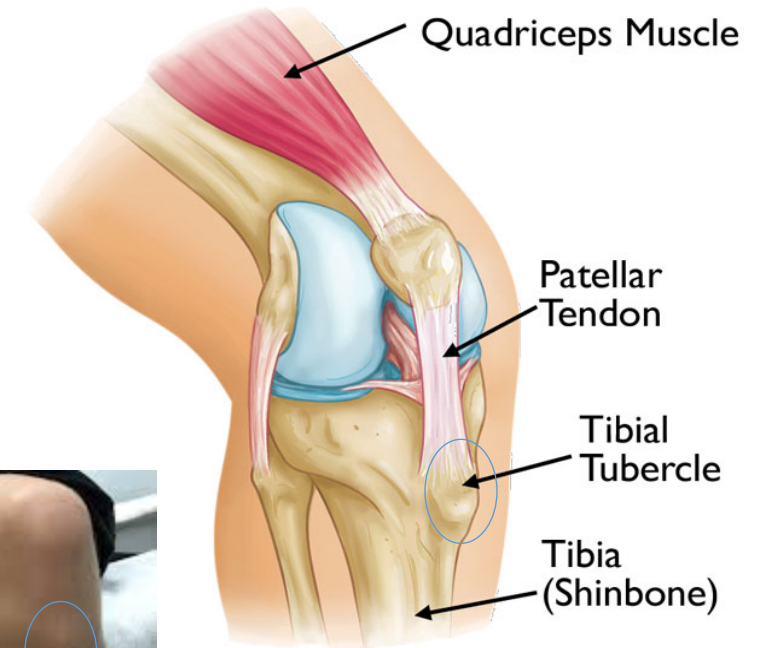
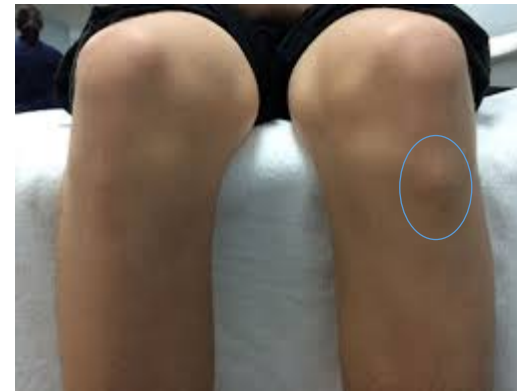20% of active adolescents

Traction at the tibial tubercle, the
insertion site for the patellar tendon

Typical age group:

Girls 10-13 years old

Boys 12-14 years old

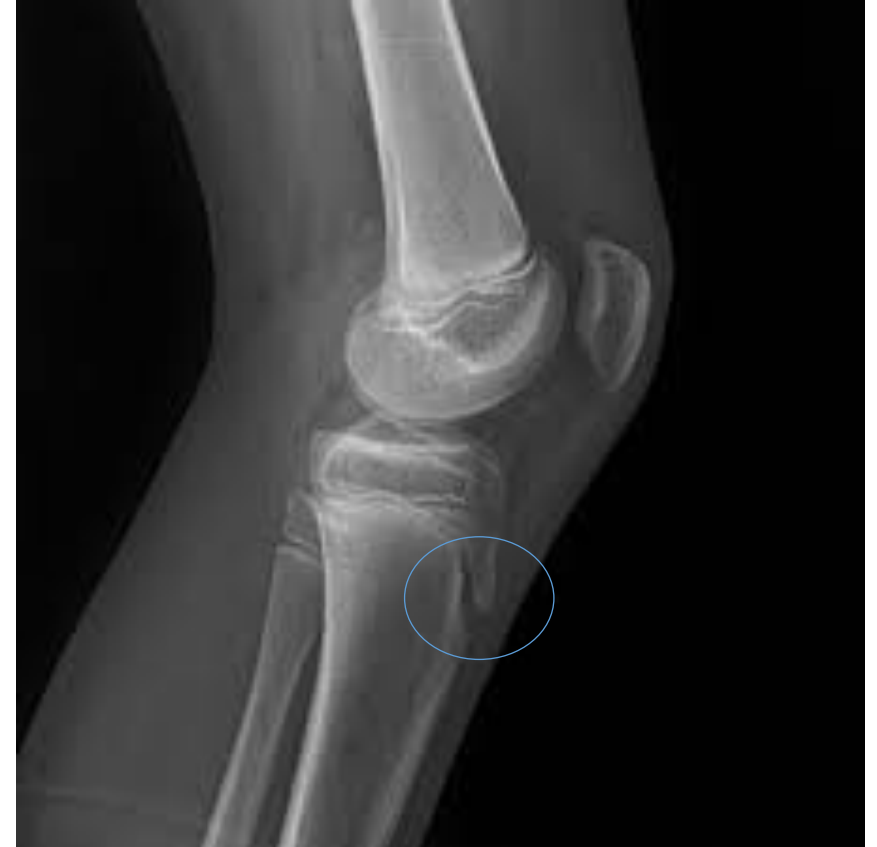

Osgood-Schlatter Disease

Sports involving explosive running and jumping, ie soccer

Self limited, 12-18 months until closure of the apophysis

May require activity modification if symptoms severe, ice, stretching



Sinding Larsen Johansson (SLJ) Syndrome

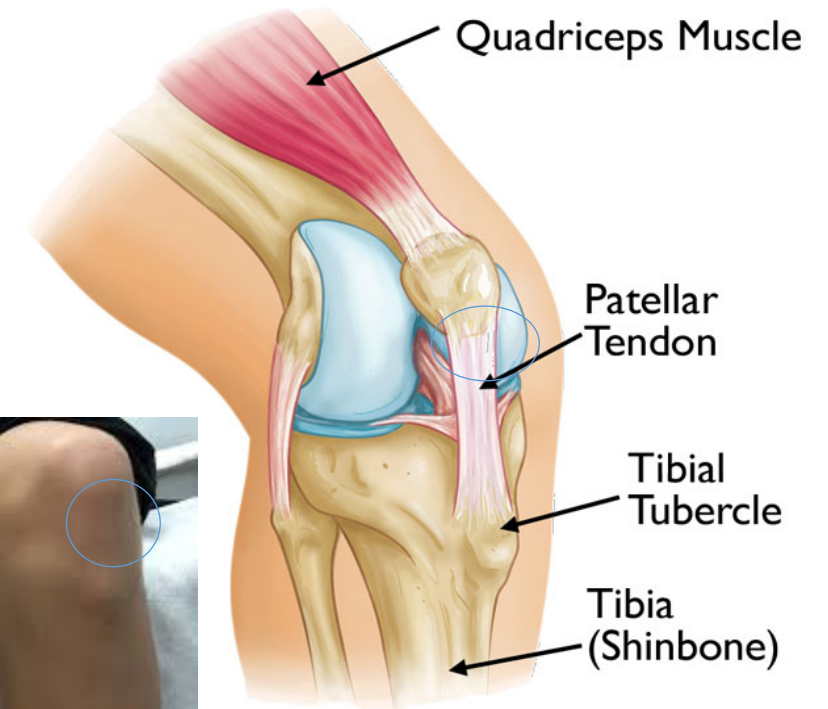
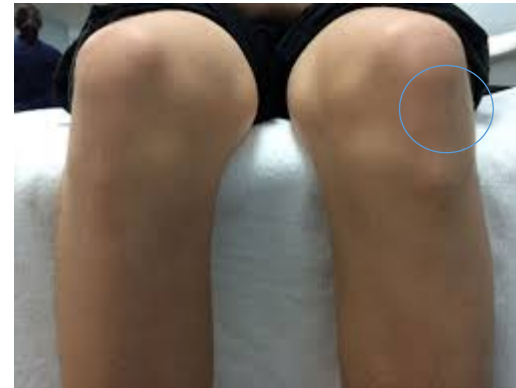Persistent traction at the apophysis at the inferior pole of the patella

Also affects the growing adolescent

Age group: 10-14 years old

Most common in sports requiring explosive running and jumping, ie soccer

Treatment: icing, NSAIDs, quadriceps stretching, bracing/knee pad for comfort, may require activity modification



Case 2

9 year old female with right heel pain

Symptoms started 3 weeks ago

Plays soccer year round and does gymnastics

Does not recall a specific injury

Pain significantly worse with running and jumping

Physical exam:

Slight limp

No swelling of the ankle or foot

Has tenderness with bilateral squeeze over the calcaneus

Tight heel cord with passive dorsiflexion



Sever's Disease

Calcaneal apophysitis

Most common cause of heel pain in the growing pediatric athlete

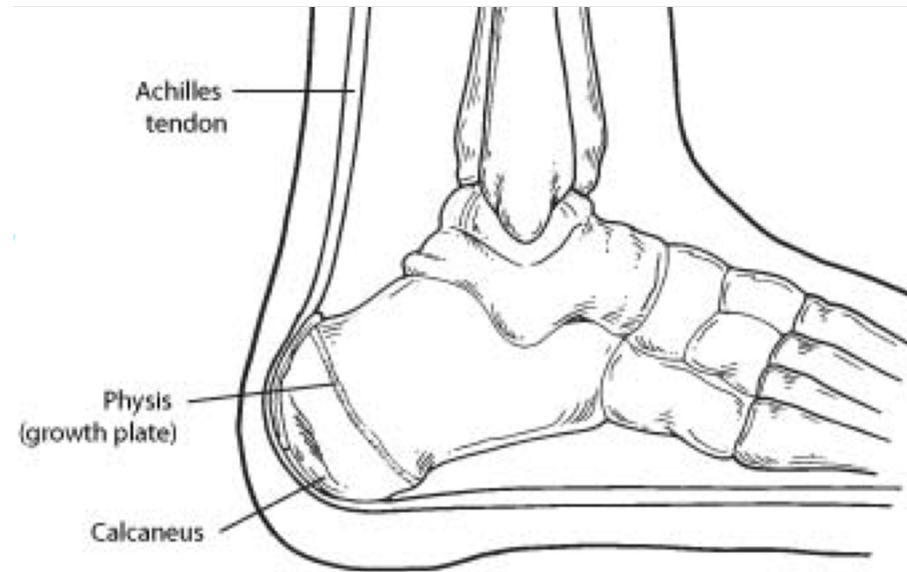
Repetitive microtrauma

Incidence of 3.7 in 1000

School-aged athletes

Bilateral 60%

Heel squeeze test 97% sensitive



EMORY
SPORTS MEDICINE
CENTER



Sever's Disease

Universally conservative treatment:

Short-term activity modification

Long-term use of stretching and strengthening to address biomechanical risk factors, such as Achilles contracture or relative calf weakness

Cryotherapy and a regimen of non-steroidal anti-inflammatory medication

Heel cups

Short term walking boot can be considered in refractory cases



Case 3

15 year old female soccer player

Anterior left hip pain for 2 weeks

No pain with walking

Has pain when striking the ball
and with sprinting

Does not recall a specific injury or
recall a pop

Physical exam:

Non-antalgic gait

No pain with single leg hop

No pain with passive log roll

No visible swelling

Has pain with palpation directly
over the AHS with exacerbation
of pain with resisted hip flexion



Apophysitis Hip/Pelvis

Traction at the apophysis of muscular insertion sites around the hip and pelvis

Treatment:

Relative rest

Activity modification

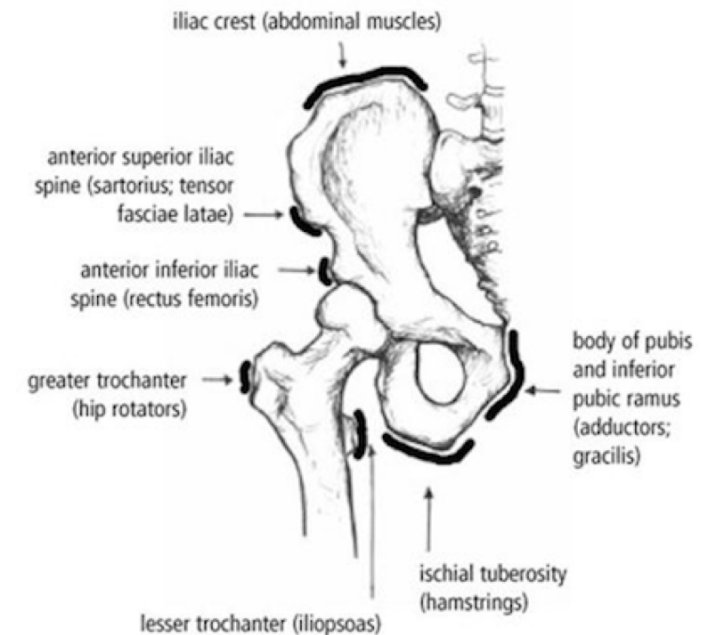
- May participate in sport at a level that does not produce pain

Anti-inflammatories

Cross training

Trunk and pelvis flexibility

Core and hip strengthening



Case 4

15 year-old male soccer player

2 month history of midline low back pain that radiates slightly to the right

No radiating pain into the legs

Does not recall a specific injury

Has progressed over the last 2 months and now is having constant pain

Plays club soccer all year

Physical exam:

Pain with palpation midline down the lumbar spine

Exacerbation of pain with extension through the low back

Good strength and normal sensation in the bilateral lower extremities



Spondylolysis

Stress fracture of the pars interarticularis

Common in sports with repetitive extension through the low back.

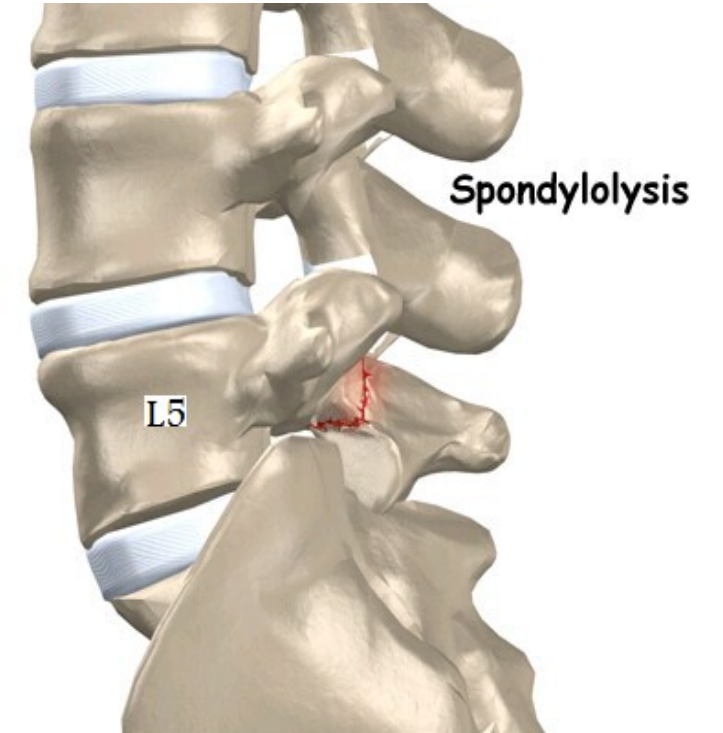
Typically present with midline extension based low back pain

Treatment regimens vary

Bracing versus non-bracing protocols

Can be out of sports 4-6 months

High risk of non-union



Red Flags

Most overuse injuries improve with rest, stretching, and icing.

Some overuse injuries that require more extensive intervention like -
prolonged time out of play

- eg osteochondral defects of the knee and ankle, bony stress fractures



Red Flags

Swelling

Persistent Limping

Limitations with range of motion

Lack of improvement with rest, stretching, icing

Back pain

When in doubt, refer for further evaluation to make sure the athlete is safe to continue playing

Have a low threshold for sending any acute injury for evaluation in which there is pain or difficulty bearing weight or significant swelling



Trauma

- THINK Growth plates!
- Ankle sprains in the soccer player



References

1. Arnold A, Thigpen CA, Beattie PF, Kissenberth MJ, Shanley E. Overuse Physical Injuries in Youth Athletes. Sports Health 2017
2. Pengel KB. Common Overuse Injuries in the Young Athlete. Pediatr Ann 2014
3. Straccolini A, Sugimoto D, Howell DR. Injury Prevention in Youth Sports. Pediatr Ann 2017
4. Straccolini A, Casciano R, Friedman HL, Meehan WP 3rd, Micheli LJ. A Closer Look at Overuse injuries in the Pediatric Athlete. Clin J Sports Med. 2015
5. DiFiori JP, Benjamin HJ, Brenner J, et al. Overuse Injuries and Burnout in Youth Sports: a Position Statement from the American Medical Society for Sports Medicine. Clin J Sport Med. 2014.
6. Wu M, Fallow R, Heyworth BE. Overuse Injuries in the Pediatric Population. Sports Medicine and Arthroscopy Review. 2016.
7. McLeod TC et al. National Athletic Trainers' Association Position Statement: Prevention of Pediatric Overuse Injuries. 2011;46(2):206–220. 2011

